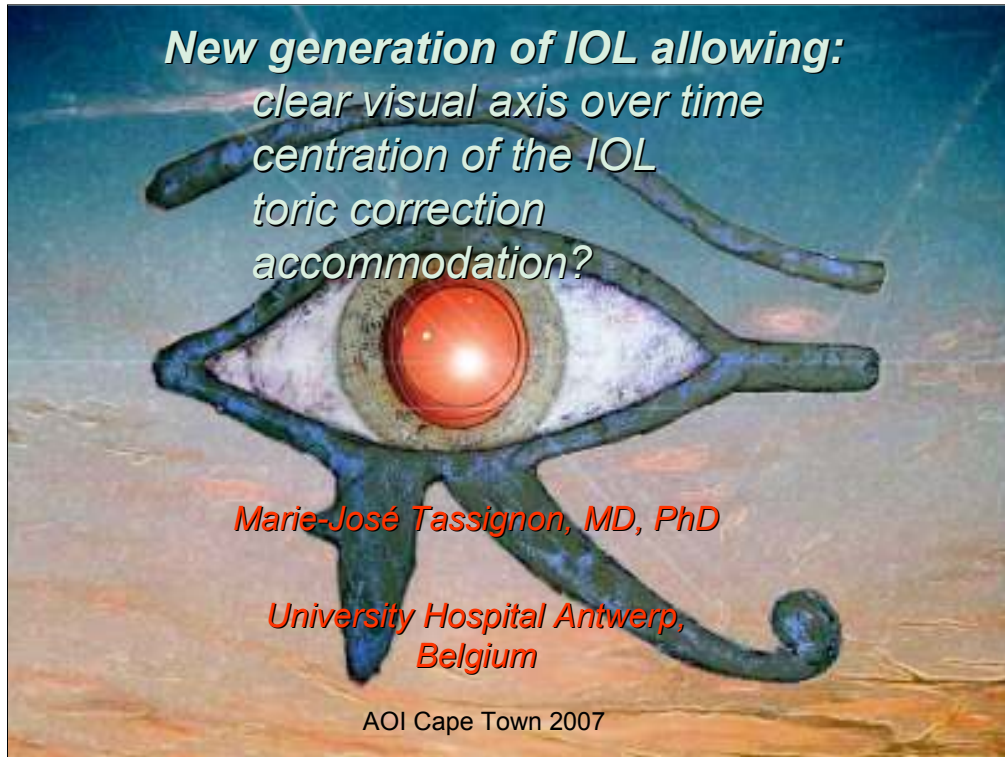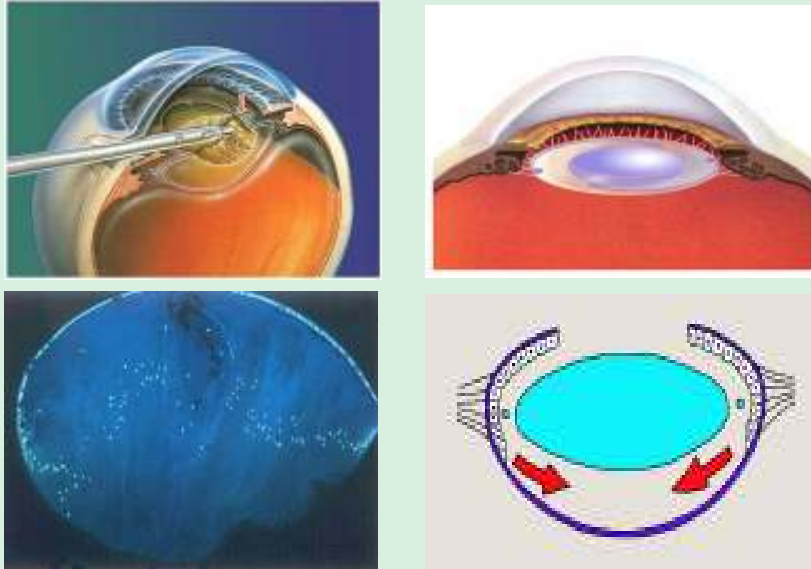


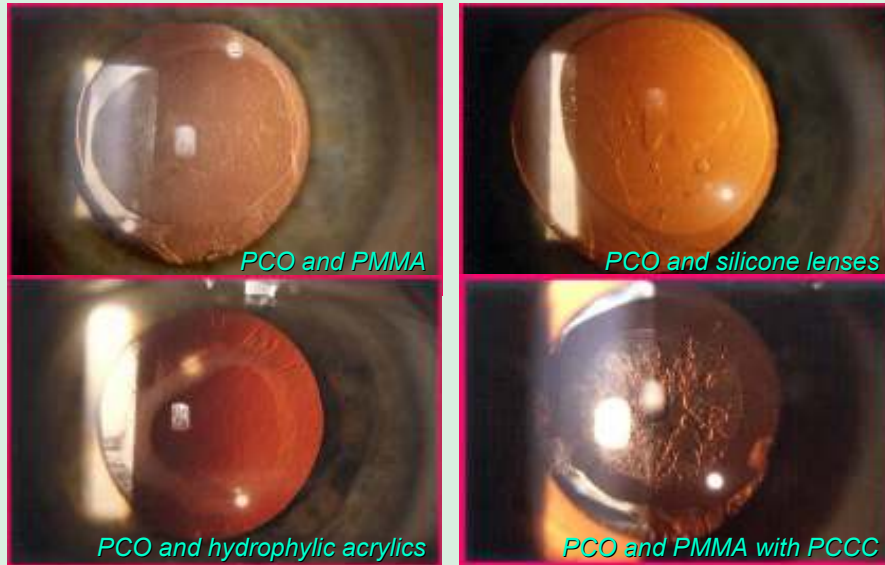
New generation of IOL allowing visual axis remaining clear for ever
Marie-José Tassignon, MD, PhD, FEBO
Setting: University Hospital Antwerp, Belgium

Cataract, cataract surgery and after cataract



Posterior capsule opacification (PCO) remains the most frequent complication after modern cataract surgery. This is due to the healing process of the capsular bag after having removed the crystalline lens and having replaced it by an artificial intraocular lens (IOL) following the technique of the lens-in-the-bag implantation technique. The lens epithelial cells (LECs) remained behind in the capsular bag, either at the level of the equator and/or at the level of the inner surface of the anterior capsule, will proliferate and/or transform once in contact with cytokines released after breakdown of the ocular barriers due to the surgical trauma.

IOL biomaterial and PCO



The biomaterial of the IOL may influence the rate of PCO occurring after lens-in-the-bag implantation as it has been shown in the literature.¹ However with improving surgical techniques, these rates have been reduced to 11 % to 13 % four to five years after surgery.

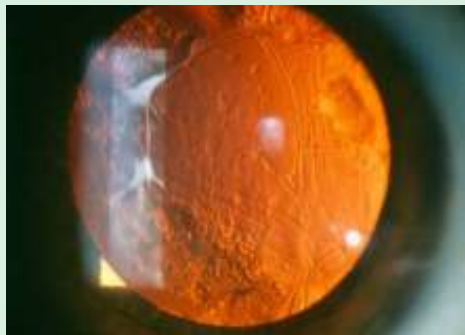Primary posterior continuous curvilinear capsulorhexis (PPCCC) has been introduced in the late 80's to early 90's in order to block the proliferation of the LECs at the level of the visual axis. We were able to show that this isolated manoeuvre as such, had only very little influence on PCO reduction. The reason relied in the possibility of the LECs to grow on the surface of the anterior hyaloid, which is composed of the same collagen as the capsular bag.²

References

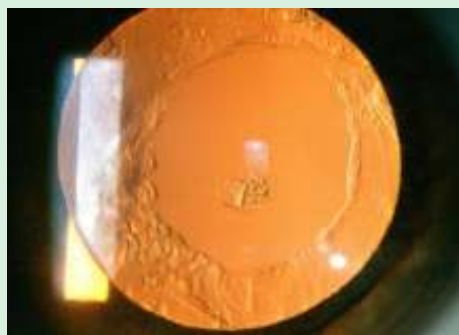
1. Davison J.A. (2004). Neodymium:YAG laser posterior capsulotomy after implantation of Acrysof intraocular lenses. *J. Cataract Refract. Surg.* 30, 1492-1500
2. Tassignon M.J., De Groot V., Vervecken F., Van Tenten Y. (1999). Secondary closure of posterior continuous curvilinear capsulorhexis in normal eyes and eyes at risk for postoperative inflammation. *J. Cataract Refract. Surg.* 24, 1333-1338

Current options to treat PCO

Before Nd -YAG laser capsulotomy



After Nd -Yag Laser capsulotomy

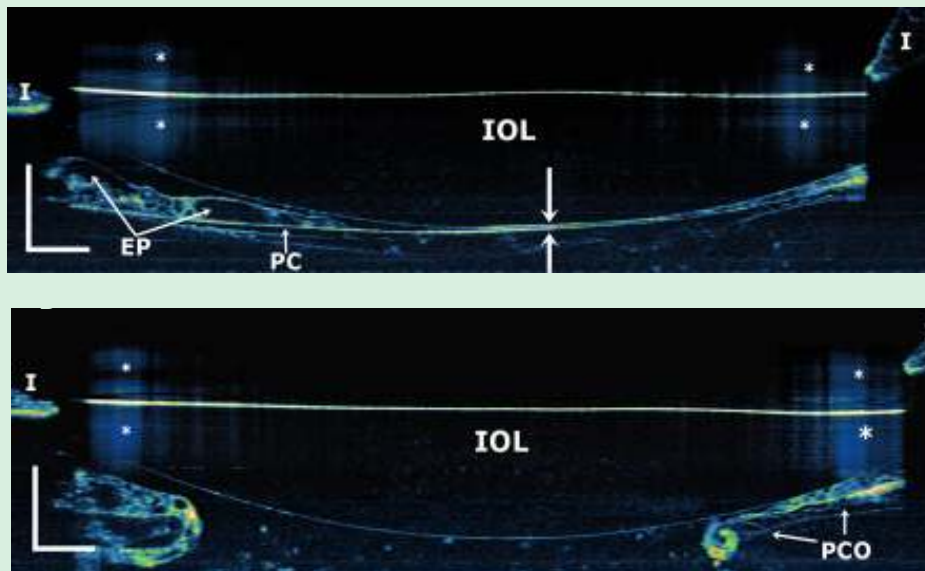


Nd:YAG laser capsulotomy is currently the most frequent option used to treat PCO though this technique presents some well-known complications³⁻⁴ and increases dramatically the cost for the National Health Services.

References

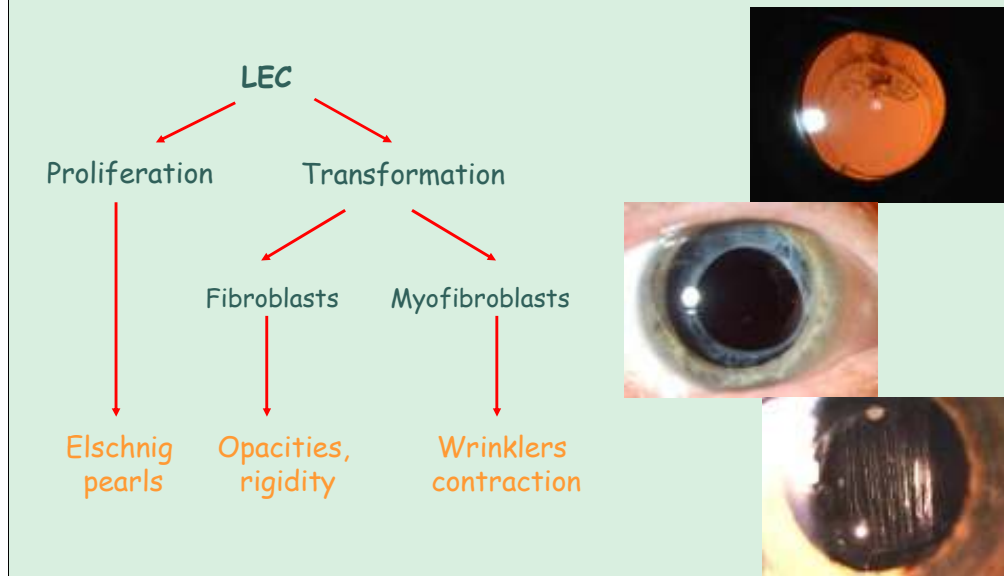
3. Apple D.J., Solomon K.D., Tetz M.R., et al. (1992). Posterior capsule opacification. *Surv. Ophthalmol.* 37, 73-116
4. Ohadi C., Moreira H., McDonnell P. (1991). Posterior capsule opacification. *Curr. Opin. Ophthalmol.* 2, 46-52

OCT after YAG laser capsulotomy



As shown with the anterior segment OCT, the major drawback of Nd:YAG laser capsulotomy is the unavoidable rupture of the anterior hyaloid resulting in a permanent disruption of this very important ocular barrier.

Capsular healing process (BAB breakdown) = capsular response

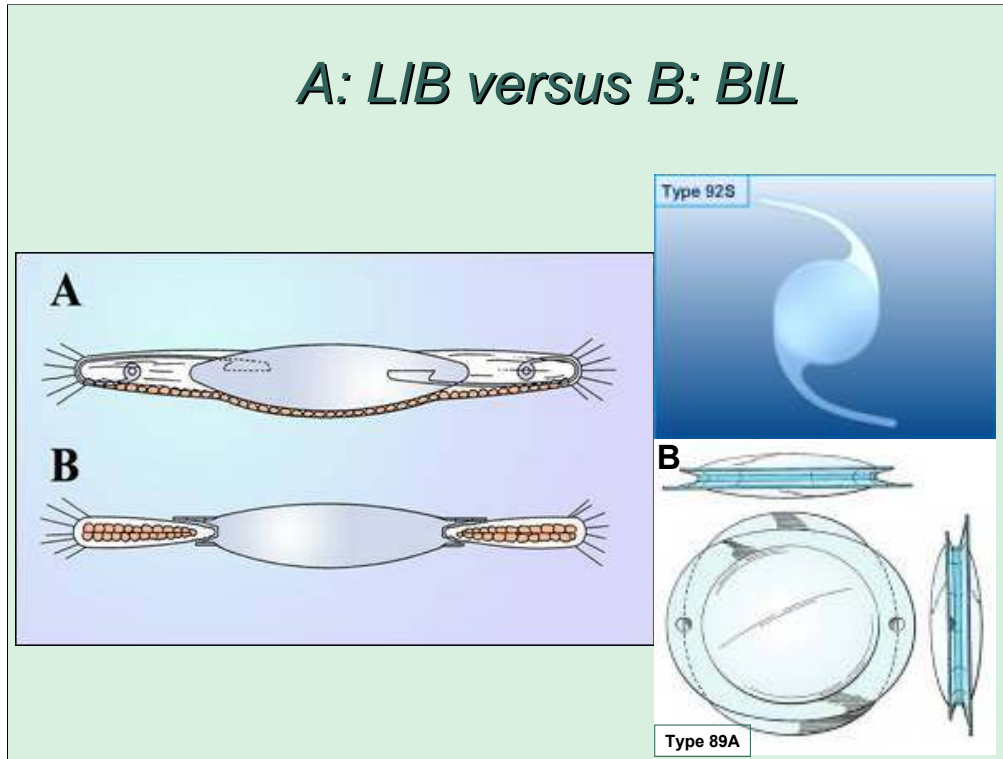


Depending on the healing process of the capsular bag many PCO types have been described going from Elschmig pearls to anterior capsular opacification, posterior capsule fibrosis and wrinkling of the anterior and posterior capsule.¹

References

1. Davison J.A. (2004). Neodymium:YAG laser posterior capsulotomy after implantation of Acrysof intraocular lenses. J. Cataract Refract. Surg. 30, 1492-1500

A: LIB versus B: BIL



The bag-in-the-lens IOL has been introduced in the late 90's and approved by the Belgian Ministry of Health to be implanted in humans in 2004.⁵ The lens is made of hydrophilic acrylic and consists of a 5 mm optic surrounded by a peripheral groove defined by the elliptical haptics, perpendicularly oriented to each other in order to accommodate the anterior and posterior capsulorhexis. Because the IOL accommodates both capsules it has been called the bag-in-the-lens implantation technique to contrast with the currently most commonly used lens-in-the-bag implantation technique where the capsular bag accommodates the IOL.

References

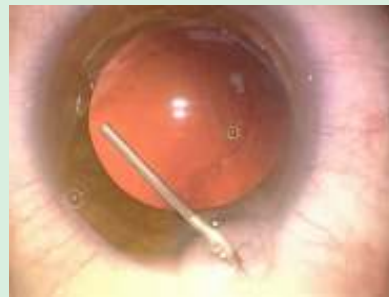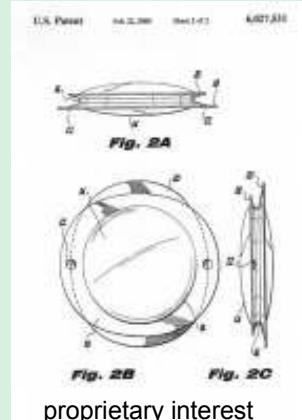
5. Tassignon M.J., De Groot V., Vrensen G.F.J.M. (2002). Bag-in-the-lens implantation of intraocular lenses. *J. Cataract Refract. Surg.* 28, 1182-1188

Introduction : BIL

Bag-in-the-lens implantation

- IOL
 - Foldable hydrophylic acrylic (type 89A-E, Morcher, Gm)
 - Central, round optic (4,4.5, 5mm)
 - Circumferential haptic: anterior lip, posterior lip, groove

- Surgical technique
 - Matched ACCC and PCCC (+/- 4.5mm)
 - 2 capsules to be inserted in the groove



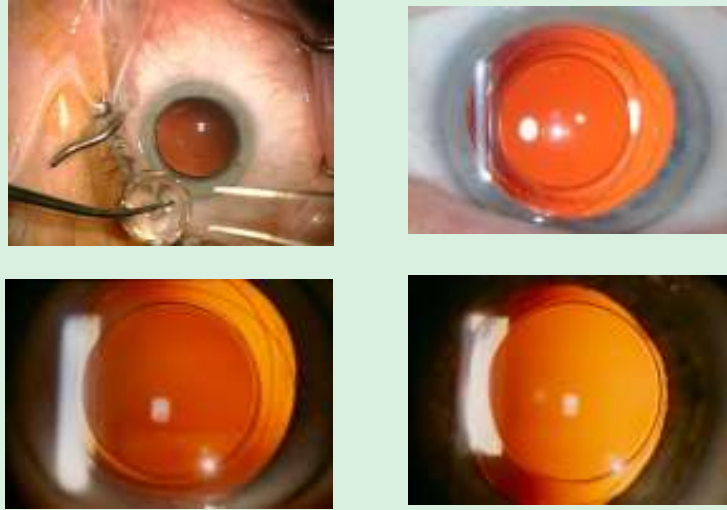As a result the surgical technique needs to be adapted slightly since this new technique requires some accurate surgical steps. The main requirement is to perform a precise sized anterior capsulorhexis, slightly smaller than the optic size of 5 mm, and a posterior capsulorhexis, matched in size to the anterior rhexis.⁶

The technique of PCCC has been largely used in the literature since its introduction by Gimbell. It is a reliable technique with very little risk for vitreous prolaps, provided the manoeuvre has been performed properly.

References

6. Tassignon M.J., Rozema J., Gobin L. (2006). A ring-shaped caliper for better anterior capsulorhexis sizing and centration. J. Cataract Refract. Surg. 32, 1253-1255

Post operative results 1 year follow-up

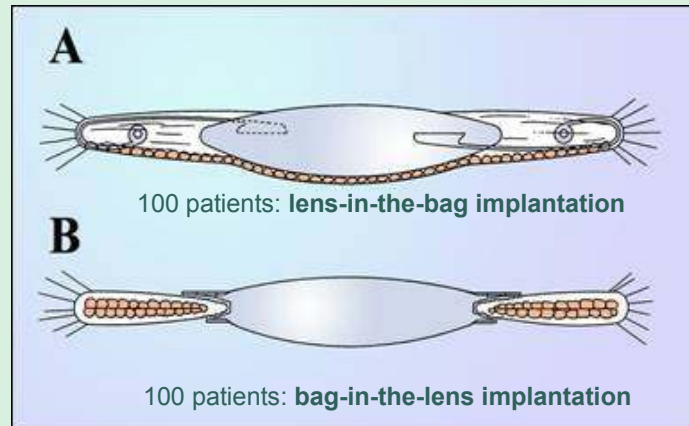


After implantation the results of the bag-in-the-lens IOL showed very surprising results with a clear visual axis remaining perfectly clear after one year of follow-up and longer.⁷

References

7. De Groot V., Leysen I., Neuhann T., Voisin L., Tassignon M.J. (2006). One year follow-up of the "bag-in-the-lens" implantation in 60 eyes. *J. Cataract Refract. Surg.* 32, 1632-1637

***Cumulative Nd-YAG laser rate after
A:lens-in-the-bag ↔B:bag-in-the-lens
IOL implantation of the same biomaterial***



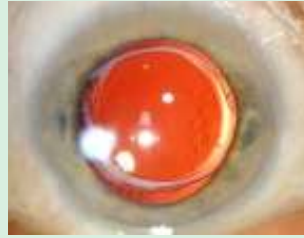We then conducted a study comparing 100 patients implanted with the bag-in-the-lens and 100 patients implanted with the lens-in-the-bag. Both IOLs were manufactured out of the same biomaterial.⁸

References

8. Leysen I., Coeckelbergh T., Gobin L., Smet H., Daniel Y., De Groot V., Tassignon M.J. (2006). Cumulative Nd:YAG laser rate after bag-in-the-lens implantation compared to lens-in-the-bag implantation. *J. Cataract Refract. Surg.* 32, 2085-2090

Patients and methods

Retrospective review medical records



■ Bag-in-the-lens

type 89A, Morcher:

- 100 eyes of 87 patients (12/1999 to 08/2004)
- One surgeon
- Age, follow-up and IOL power

■ Lens-in-the-bag

type 92S, Morcher:

- 100 eyes of 93 patients (02/2000 to 08/2004)
- One surgeon
- Age, follow-up and IOL power

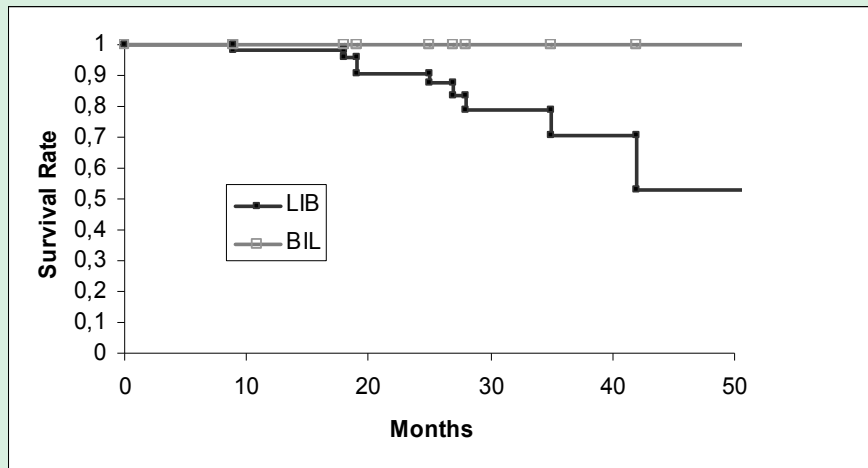
Parameters like surgeon, age of the patients, dioptric power, follow-up period were matched for each group. The aim was to study the Nd:YAG laser rate in both groups.

Comparison between both groups

Parameters	BIL group (n=100)	LIB group (n=100)
<u>Age (years)</u>		
Mean	68,56	69,40
Range	39-88	18-90
<u>Follow-up (months)</u>		
Mean	17,03	16,86
Range	2-57	2-56
<u>IOL power (D)</u>		
Mean	20,88	21,05
Range	15,5-25	13-25

Parameters like surgeon, age of the patients, dioptric power, follow-up period were matched for each group. The aim was to study the Nd:YAG laser rate in both groups.

Kaplan - Meier survival curves



Using the Kaplan-Meier survival test we could show that no Nd:YAG laser was needed in the bag-in-the-lens group, while the treatment was increasingly used with time in the lens-in-the-bag group.

Visual axis re proliferation (VAR) after BIL

Total number of implantations : 850

December 1999 - December 2006

Follow up : one month – 6 years

ICO certification needs 300 eyes with 1 year follow-up

816 adult patients including: uveitis, diabetes, glaucoma, IOL exchange,

...

34 eyes of babies and children

VAR rate:

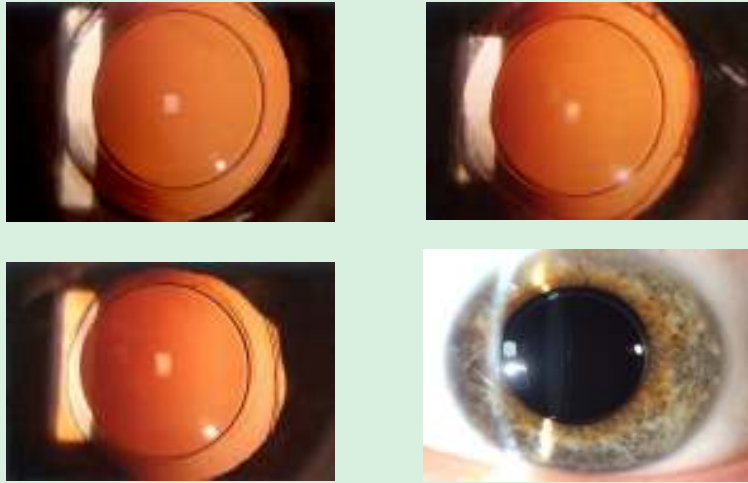
0% !!

On a total number of 850 eyes implanted with the bag-in-the-lens between December 1999 and December 2006, including 36 eyes of babies and children, the visual axis re proliferation was zero within a follow-up of 6 months to 6 years. On slit lamp examination, the anterior hyaloid is clearly visible showing no re proliferation at all.9-10

References

9. Tassignon M.J. (2007). Technology and needs for tomorrow's treatment of cataract. Proc. SPIE. 1605
10. Tassignon M.J., De Veuster I., Godts D., Kosec D., Van den Dooren K., Gobin L. (2007). Bag-in-the-lens intraocular lens implantation in the pediatric eye. J. Cataract Refract. Surg. 33, 611-617

Four years follow-up of 1 patient 2000 - 2004



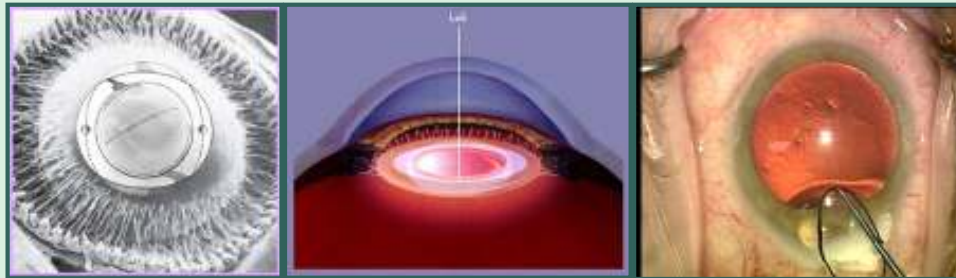
On a total number of 850 eyes implanted with the bag-in-the-lens between December 1999 and December 2006, including 36 eyes of babies and children, the visual axis reformation was zero within a follow-up of 6 months to 6 years. On slit lamp examination, the anterior hyaloid is clearly visible showing no reformation at all.9-10

References

9. Tassignon M.J. (2007). Technology and needs for tomorrow's treatment of cataract. Proc. SPIE. 1605
10. Tassignon M.J., De Veuster I., Godts D., Kosec D., Van den Dooren K., Gobin L. (2007). Bag-in-the-lens intraocular lens implantation in the pediatric eye. J. Cataract Refract. Surg. 33, 611-617

Surgeon controlled IOL centration

Centration along the line of sight using the 1 and 3 Purkinjes

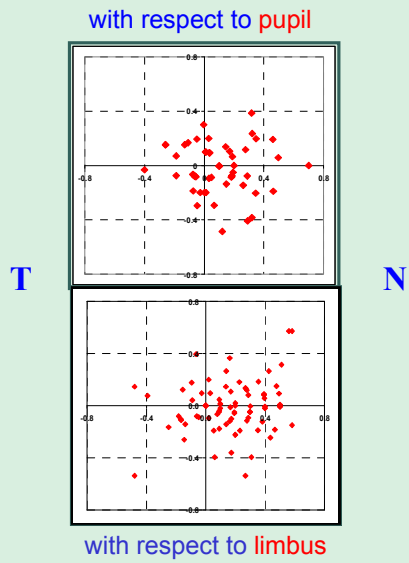
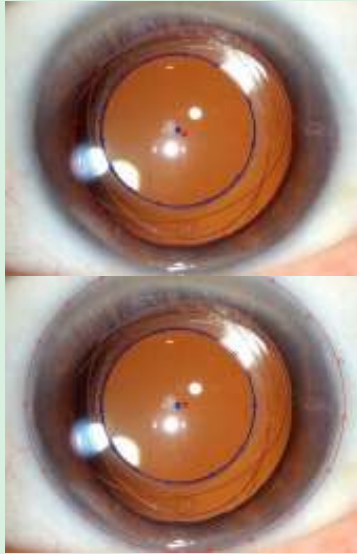


Besides the long-lasting transparency of the visual axis, the bag-in-the-lens IOL presents the additional advantage to be positioned along the line of sight on a surgeon-controlled way. A ring caliper has been developed in order to size and center the bag-in-the-lens along the first and third Purkinje reflexes.¹¹

References

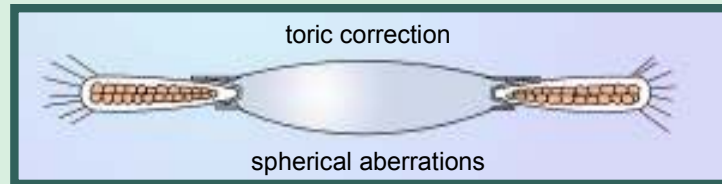
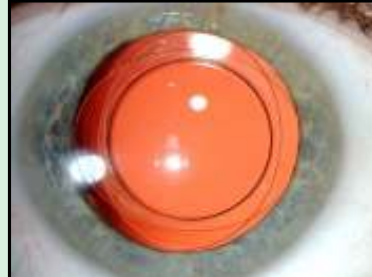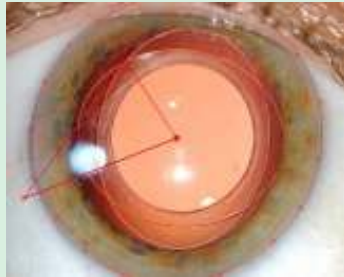
11. Verbruggen K.H.M., Rozema J.J., Gobin L., Coeckelbergh T., De Groot V., Tassignon M.J. (2007). IOL centration and visual outcome after bag-in-the-lens implantation. *J. Cataract Refract. Surg.* (accepted)

Surgeon controlled BIL centration (50 eyes)



By studying 50 eyes implanted with this lens, and using the Purkinje reflexes for the purpose of the IOL centration, we found a slightly nasal decentration. This corresponds with the physiologically angle Kapla.

35 eyes: rotation <math>< 1.5^\circ</math> 850 eyes VAR: 0%
($p = 0.134$)

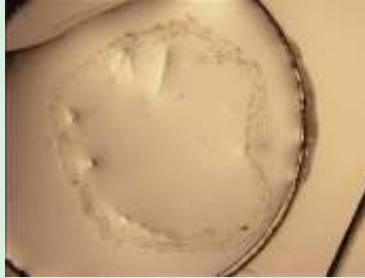

When evaluating the rotational stability of the bag-in-the-lens we found a very high stability of the bag-in-the-lens with a rotation of less than 1.5° .

These results allow the incorporation of toric correction in the lens optic and compensation of spherical aberrations at the posterior surface of the lens optic.

Uveal response on capsular bag healing process

4 weeks culture of post mortem donor eyes with TGF



Capsular bag without IOL

Capsular bag with BIL



Capsular bag with LIB



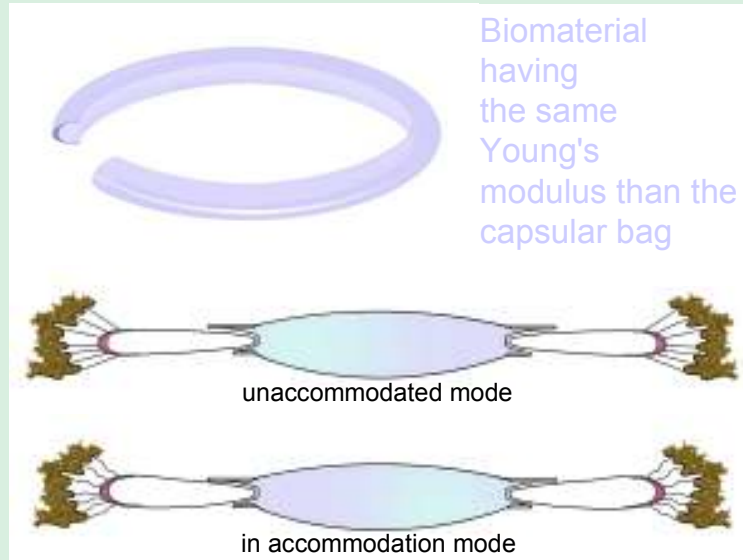
We then studied the uveal response in vitro. Post-mortem human lens capsules were prepared and put in culture for four weeks. We considered three groups: virgin capsular bags, capsular bags equipped with bag-in-the-lens IOLs and capsular bags equipped with lens-in-the-bag IOLs. Tissue growth factor (TGF) was added to the culture medium in order to stimulate the proliferation of the LECs. The results were very striking, showing that only the capsules equipped with the bag-in-the-lens remained transparent in these conditions (paper submitted).

*Capsular equator remains clear
4 patients: 1 year follow-up*



The results of the experimental and clinical evaluation merge to the same conclusion that after implantation of the bag-in-the-lens, the visual axis remains clear for ever.

Capsular bag accommodation ring to restore the capsular equator angle



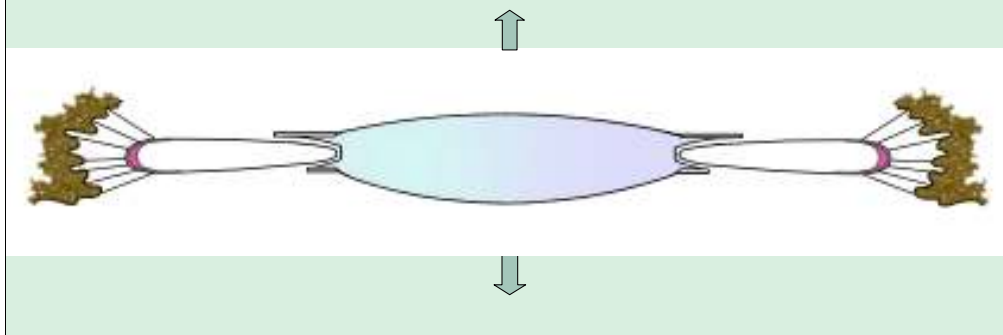
The toric and aspheric bag-in-the-lens is in development now and hopefully available in the very near future.

It is not clear however which degree of asphericity should be included in the lens since no benchmarks based on a large-scale epidemiological study are available up to now.

Restoration of accommodation is another concern. Because the bag-in-the-lens does not interfere with the peripheral capsular bag, we designed a capsular bag accommodation ring. This ring aims at restoring the capsular equator angle in order to put the zonular fibers in their physiological condition (US Patent Application N° 11/110,463).

Accommodation after BIL (RAF)

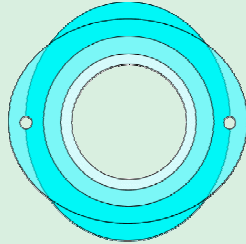
- Children: mean accommodation of 3.5D
- Adults: axial length of 22 or less: 2.75D
- Before going multifocal: restoring zonular fibers tension



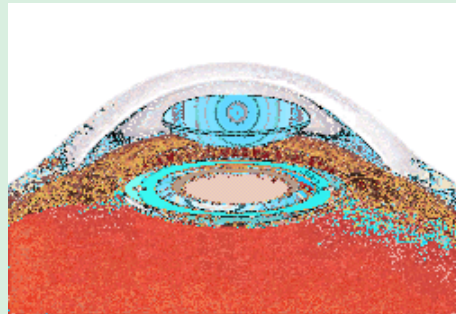
The aim is to promote the anterior displacement of the capsular bag/IOL complex during accommodation.

This idea was based on our clinical experience that children and adults with axial lengths of 22 mm or less did present accommodation up to 3.5 D, which allows reading without spectacles.

Refractive correction over time: option



Removable, replaceable customized optic
Patent pending



A last development which is in development is the removable optic IOL (US Patent application N° 11/110,463). It consists in separating the optic part from the haptic part. This would allow changing the optic part for different reasons: inadvertent IOL miscalculation, drug delivery optic for chronic uveitis or to prevent endophthalmitis, incorporation of magnification devices in case of macular problems, ...

What has been considered as unrealistic by many ophthalmologists has been proven to work.

The sceptics argue about the difficulty to make a sized capsulorhexis, which isn't an issue anymore since the introduction of the ring caliper. However, tracking devices could help by improving the centration of the anterior and posterior capsulorhexis along the visual axis, which would be more physiologic than using the Purkinje reflexes.

The most challenging objective is accommodation. In a few months we will be able to report whether the accommodative equatorial ring is of some help.

THANK YOU FOR YOUR ATTENTION



THANK YOU FOR THE INVITATION